

Anterior Cruciate Ligament Ruptured Concomitant Meniscus Discoid in Young Patient: A Rare Case Report

I Gusti Ngurah Wien Aryana, I Ketut Wahyu Trisaputra, Febyan

Department of Orthopaedic & Traumatology, General Central Hospital of Prof. I.G.N.G. Ngoerah/
Faculty of Medicine, Udayana University, Bali, Indonesia

ABSTRACT

Background: Abnormalities of the human meniscus, including discoid meniscus, double-layered meniscus, and ring-shaped meniscus, have been reported. The prevalence of discoid meniscus is extremely rare, with an incidence of 0.9%–2.4% in Asian population. Traditionally, discoid meniscus concomitant anterior cruciate ligament (ACL) ruptured are extremely rare case. The aim of this study is to discuss a rare case to provide diagnosis and management properly by using arthroscopy.

Case Presentation: A 21-year-old male Balinese, he complained of pain on his right knee after fast walking for two months and unstable knee in the past 1 year ago. On physical examination, the range of motion was limited due to the pain for flexion more than 90°. Special test such as Lachman test positive, Anterior drawer test positive. The patient had medial joint line tenderness, and a McMurray test elicited pain on the medial joint line. Meanwhile, on MRI examination of the right knee showed a discoid medial meniscus with a horizontal cleavage tear and a discoid lateral meniscus with incomplete tear. We performed partial meniscectomy of incomplete discoid medial meniscus and resection of pathologic medial patellar plica. We performed surgical reconstruction to the ACL ruptured after meniscus was repaired.

Results: We presented a 21 year old male with discoid meniscus concomitant ACL rupture to his right knee. After the patient was performed with partial meniscectomy of incomplete discoid medial meniscus and resection of pathologic medial patellar plica and following surgical reconstruction to the ACL ruptured. The patient had no limitation of motion or pain 1 years after operation and he had no complaint and satisfied with the result by radiograph.

Conclusion: We concluded that, This rare case of medial discoid meniscus concomitant with the ACL ruptured must be reconstructed. The treatment of discoid meniscus should be consider its tear pattern and whether it is symptomatic. With the development of arthroscopic techniques, the treatment of discoid meniscus has gradually changed from total meniscectomy or partial meniscectomy.

Keywords: anterior cruciate ligament, meniscus, discoid, knee, arthroscopy.

Correspondence:

I Gusti Ngurah Wien Aryana. Department of Orthopaedic & Traumatology, General Central Hospital of I.G.N.G Ngoerah Central Hospital/ Faculty of Medicine, Udayana University, Bali, Indonesia. Email: wienaryanaortho@gmail.com. Mobile: +62811-385-263.

Cite this as:

Aryana IGNW, Trisaputra IKW, Febyan (2023). Anterior Cruciate Ligament Ruptured Concomitant Meniscus Discoid in Young Patient: A Rare Case Report. *Indones J Med.* 08(03): 317-324. <https://doi.org/10.26911/theijmed.2023.08.03.09>.



Indonesian Journal of Medicine is licensed under a Creative Commons Attribution-Non Commercial-Share Alike 4.0 International License.

BACKGROUND

Meniscus is a white, glossy structure located in the knee between the femoral condyle and tibial plateau on the medial and lateral sides of both knees. The meniscus serves to im-

prove joint congruence and stability, transmit load, and absorb tension (Kim et al., 2006; Ryu et al., 2015). Abnormalities of the human meniscus, including discoid meniscus, double-layered meniscus, and ring-sha-

ped meniscus, have been reported. The prevalence of discoid meniscus is extremely rare, with an incidence of 0.9%-2.4% in Asian population (Kim et al., 2006; Ryu et al., 2015). There are some reports of symptomatic medial and lateral meniscus. The first case of both medial and lateral discoid menisci in the same knee was reported by Jeannopolous in 1950 (Jeannopoulos, 1950) They found lateral and medial meniscus incidentally during arthroscopy. These authors believe that this anomaly seems to be congenital (Arnold and van Kampen, 2000)

In theoretically, there are three types discoid lateral meniscus: (a) complete, (b) incomplete, and (c) Wrisberg ligament type. According to this classification, the ligaments and its attachment are normal for complete and incomplete types. The surface of tibial plateau is covered by discoid meniscus completely or partially. In the Wrisberg type the meniscus has a thick posterior horn. The connection between the tibia and discoid meniscus is provided only by the Wrisberg ligament. The posterior horn of discoid meniscus is hypermobile and results in impingement by entering the joint space of the knee (Taschdjian MO, 1990). Traditionally, discoid meniscus concomitant anterior cruciate ligament (ACL) ruptured are extremely rare case (Fujii et al., 2017)

In this case report, we presented the first case in the literature of medial and lateral discoid meniscus with anterior cruciate ligament (ACL) ruptured who underwent ACL reconstruction. The purpose of this study was to determine the relationship between clinical, radiological findings, and arthroscopic assessment of discoid meniscus and to evaluate the results of partial meniscectomy combined ACL reconstruction.

CASE PRESENTATION

A 21-year-old male Balinese, complained of pain on his right knee after fast walking for

two months and unstable knee in the last 1 year ago. Upon further history taking, he is currently an undergraduate student, and his family history revealed no history of rheumatic, autoimmune nor other chronic diseases. On physical examination, the range of motion was limited due to the pain for flexion more than 90°. Special test such as Lachman test positive, Anterior drawer test positive and there was no effusion (see figure 1). The patient had medial joint line tenderness, and a McMurray test elicited pain on the medial joint line. Radiographs of the right knee showed lateral joint space widening, high fibular head, and increased concavity and subchondral sclerosis of the medial tibial plateau (see figure 2). MRI of the right knee showed a discoid medial meniscus with a horizontal cleavage tear (see figure 3) and a discoid lateral meniscus with incomplete tear (see figure 4).

RESULTS

According to physical examination, imaging evaluations and arthroscopic examination of the right knee confirmed the patient was diagnosed discoid medial and lateral with incomplete tear menisci (see Fig. 4) with ACL ruptured on the right knee. The discoid medial meniscus had an anomalous insertion to the anterior cruciate ligament (ACL). We found also a pathologic medial patellar plica with fibrotic, thickening, and tear. There was cartilage fasciculation on the medial facet of patella. We performed partial meniscectomy of incomplete discoid medial meniscus and resection of pathologic medial patellar plica. We performed surgical reconstruction to the ACL ruptured after meniscus was repaired.

After reconstruction surgery, we encourage the patient to follow the rehabilitation protocol by applying knee immobilization at 00 extension and periodically increase until 90° flexion in the first week. After discharge,

the patient used a brace that was set on the flexible range so that the patient could begin the active and passive range of motion exercise.

We evaluated the clinical outcomes using the visual analogue scale (VAS) pain scale, International Knee Documentation Committee (IKDC), and American Orthopedic Foot and Ankle Score (AOFAS) scores. The follow-up results revealed favorable recovery and improvement in all objective parameters. Subjective and objective pain was absent at the 6- months follow-up compared to the score of 3–4 pre-surgery. At 12-months post-operative follow-up, the IKDC

assessment was 100%. The AOFAS assessment was 90% at 12-months follow-up and the patient presented good ankle motoric power with no complaint regarding the ankle function. The range of motion for both ankle eversion and first ray plantar flexion were not limited. The patient was unstable before surgery on the anterior drawer test, and Lachman's test indicated a score of +3. Post-operatively, the patient had negative results on Lachman's test and anterior drawer test. The patient had no complaint and satisfied with the result by radiograph (see Fig. 5).

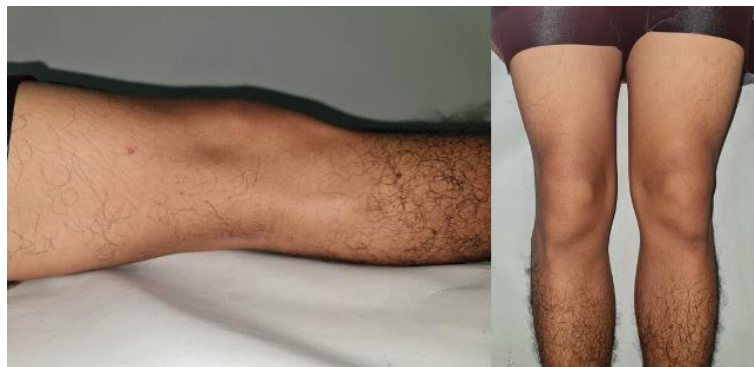

Figure 1. Clinical Picture of the Patient

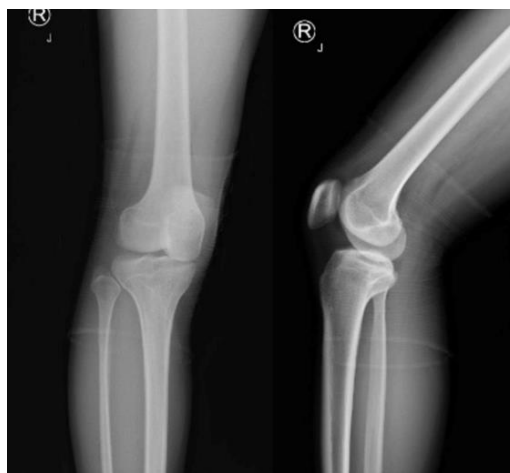

Figure 2. Anteroposterior and lateral standing x-ray of the right knee showed, widening of lateral joint space and increased concavity and subchondral sclerotic of the medial tibial plateau.

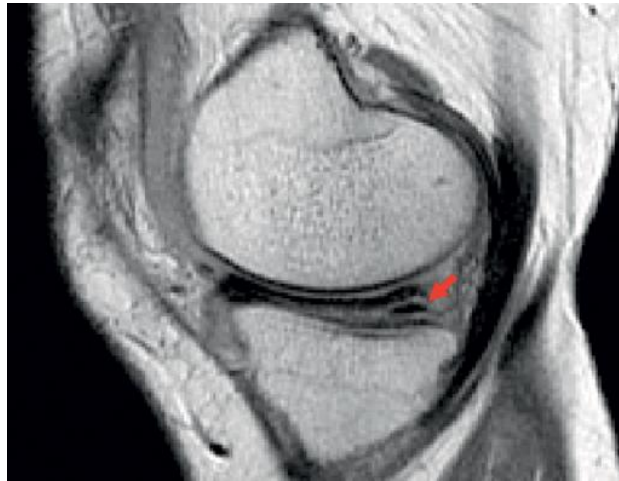

Figure 3. Magnetic resonance imaging of the right knee revealed, T1-weighted sagittal MRI of the right knee visualized medial discoid meniscus with a horizontal tear (confirmed by red arrow)

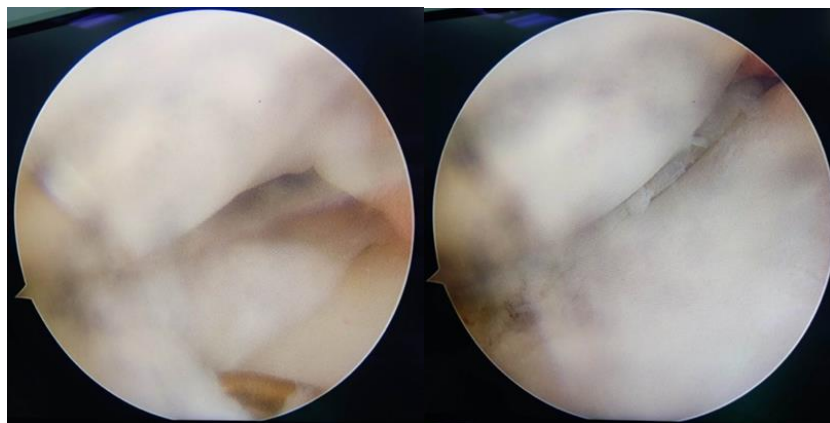


Figure 4. Arthroscopic examination view of the right knee, revealed incomplete medial and lateral discoid meniscus

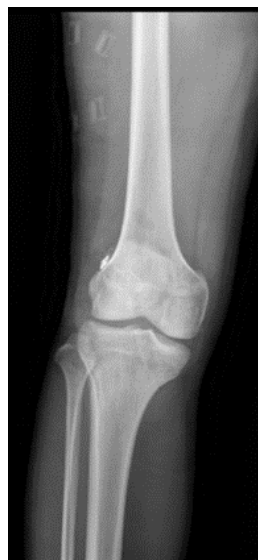

Figure 5. X ray of the right knee showed anatomical position.

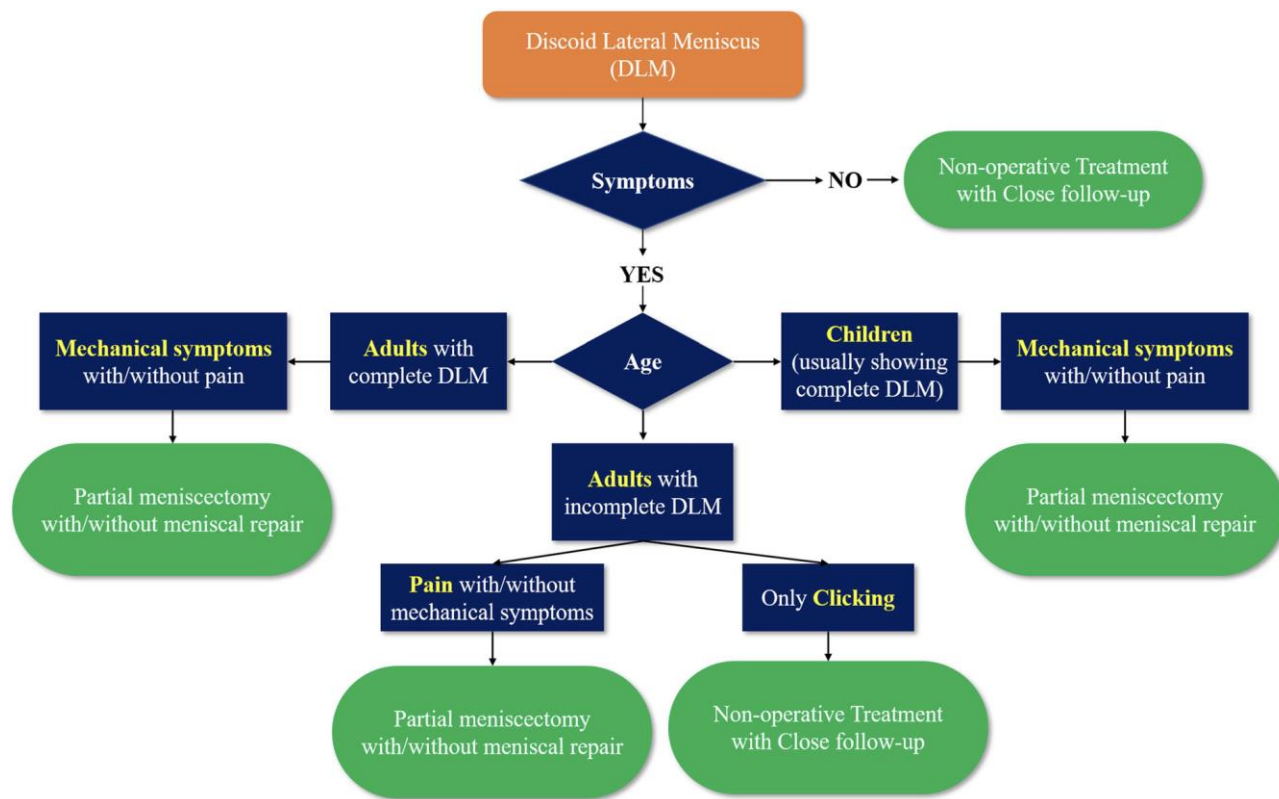


Figure 6. Management algorithm for discoid meniscus

DISCUSSION

We presented a 21-year-old male with discoid meniscus concomitant ACL rupture to his right knee. Discoid medial and lateral meniscus are more common among Asians than that among Caucasians (Kim and Lubis, 2010). The incidence rate of discoid medial and lateral menisci reported was from 0.03% to 0.3% (Fujii et al., 2017). Smillie et al postulated that the meniscus existed as a cartilaginous disc at an early stage of development, and that the congenital discoid meniscus was attributable to the congenital developmental arrest leading to resorption processing failure of the central meniscus at varying stages of embryologic development. Kaplan et al found in an embryological study that the meniscus did not appear to be a discoid form at any stage of normal development of the fetus. Discoid menisci were definite pathologic entities that developed un-

der specific conditions, he concluded, and they resulted from hypermobility on the unstable meniscal attachment of the posterior horn. Other studies found that both the medial and lateral meniscus showed a semi-lunar shape in the early stages of prenatal development. But mild to moderate instability (absence of the meniscofemoral attachment) may result in filling in of the central area of the meniscus (Clark and Ogden, 1983; KAPLAN, 1957; SMILLIE, 1948).

In radiographs examination are often normal in patients with a discoid meniscus; however, they may reveal some radiologic features of discoid meniscus, such as widening of the lateral joint space, a squared-off appearance of the lateral femoral condyle, cupping of the lateral tibial plateau, Elevation of the fibular head, and tibial eminence flattening (Kramer and Micheli, 2009). On MRI, a discoid meniscus can be diagnosed

when the ratio of the minimal meniscal width to the maximal tibial width is more than 20% on the coronal image, and the ratio of sum of the width of both lateral horns to the maximal meniscal diameter on the sagittal image is more than 75% (Samoto et al., 2002).

Schonholtz et al stated that, the technique used in the management included a careful resection of the menisci back to firm, longitudinal fibers (Schonholtz et al., 1993). In this case, we proposed surgical and techniques to manage medial and lateral meniscus with ACL rupture. The procedures could be performed simultaneously because we believe that ACL reconstruction must be performed if meniscus has already stable (immobile). Our senior author has described arthroscopic one-piece excision technique for the treatment of symptomatic medial and lateral discoid meniscus. The result depends on the amount of retained meniscal tissue, the associated lesions, the activity level of the individual, and the length of the follow-up. In general, the results of meniscectomy for discoid meniscus are good. Our patient also had no complain and she has satisfactory with the result of both of her surgeries. However, a longer follow-up period is still needed since discoid meniscus has been reported as one of the risk factors for articular cartilage lesions. The duration of symptoms and meniscal shape showed significant relation with articular cartilage lesion (Chernchujit and Prasetya, 2017).

The treatment of discoid medial meniscus depends on the tear pattern, including longitudinal tear, horizontal tear, bucket-handle tear. Surgical techniques include saucerization, partial meniscectomy, and total meniscectomy. Total meniscectomy and partial meniscectomy are currently not first line treatment due to the potential of degenerative arthritis (Lee et al., 2017). Therefore, the treatment of discoid medial

meniscus is usually performed with arthroscopic saucerization. Nonetheless, there is a lack of consensus on how much peripheral rim of medial meniscus should be preserved when performing saucerization. In this case, we recommend preserve 6–8 mm peripheral rim of meniscus, referring to the guideline for discoid lateral meniscus (Perkins et al., 2021; Yamaguchi et al., 2022)

Kim et al explain that the surgical indication should depend on the age of the patients with discoid meniscus. Children with mechanical symptoms, such as snapping and clicking often present with a complete discoid meniscus, which is prone to tearing. Thus, careful, and thorough evaluation is necessary because a discoid meniscus with peripheral tears is often detected during arthroscopy in pediatric patients with complete discoid meniscus presenting with only snapping. Meanwhile, older patients presenting slight clicking or snapping without pain or locking symptoms usually have an incomplete discoid meniscus; thus, close follow-up is required rather than operation because they have adapted to the knee with a discoid meniscus. However, if any patients experience pain or locking symptoms, surgical intervention is warranted (Kim et al., 2020) (See Fig. 6).

In conclusion, Arthroscopy has more value for the diagnosis of discoid meniscus. Therefore, it is more prone to tearing than a normal meniscus. Asymptomatic discoid menisci do not require treatment. However, if there are symptoms, operative treatment is necessary. Since total meniscectomy leads to a high risk of osteoarthritis, total meniscectomy should be avoided except for unsalvageable cases. Partial meniscectomy (saucerization) with preservation of a stable peripheral rim combined with or without peripheral repair is recommended, and good clinical results have been reported. The results of partial meniscectomy are hopeful in terms

of function and satisfactory results, even in childhood or adult. Hence, ACL ruptured that need to reconstruction surgery may be found in discoid meniscus cases to achieve excellent outcome. However, longer-term studies will be necessary and helpful for the future.

AUTHOR CONTRIBUTION

I Gusti Ngurah Wien Aryana is the main author who determines the concept and review. I Ketut Wahyu Trisaputra searching for literature, editing and reviews. Febyan determines the concept and review

FINANCIAL AND SPONSORSHIP

None.

ACKNOWLEDGEMENT

None.

CONFLICT OF INTEREST

We declare that the study was conducted in the absence of any commercial or financial relationships that could be construed as a potential conflict of interest.

REFERENCE

- Arnold MP, van Kampen A (2000) Symptomatic ring-shaped lateral meniscus. *Arthroscopy: J. Arthrosc. Relat. Surg.* 16(8): 852–854. Doi: 10.1053/jars.-2000.8244.
- Chernchujit B, Prasetya R (2017). Both Posterior Root Lateral-Medial Meniscus Tears with Anterior Cruciate Ligament Rupture: The Step-by-Step Systematic Arthroscopic Repair Technique. *Arthrosc Tech.* 6(5): e1937–e1943. Doi: 10.1016/j.eats.2017.07.018.
- Clark CR, Ogden JA (1983) Development of the menisci of the human knee joint. Morphological changes and their potential role in childhood meniscal injury. *J Bone Joint Surg Am.* 65(4): 538–47.
- Fujii M, Furumatsu T, Miyazawa S, Tanaka T, Inoue H, Kodama Y, Ozaki T. (2017) Formation of ring-shaped lateral meniscus following anterior cruciate ligament reconstruction: A case report. *Int J Surg Case Rep.* 31: 229–232. Doi: 10.1016/j.ijscr.2017.01.060.
- Jeannopoulos CL (1950) Observations on discoid menisci. *J Bone Joint Surg Am.* 32(3): 649–52.
- Kaplan EB (1957) Discoid lateral meniscus of the knee joint; nature, mechanism, and operative treatment. *J Bone Joint Surg Am.* 39(1): 77–87.
- Kim Jun Ho, Ahn JH, Kim Joo Hwan, Wang JH. (2020) Discoid lateral meniscus: importance, diagnosis, and treatment. *J Exp Ortop.* Doi: 10.1186/s40634-020-00294-y.
- Kim SJ, Lubis AM (2010) Medial and lateral discoid menisci: a case report. *BMC Sports Sci Med Rehabil.* 2(1): 21. Doi: 10.1186/1758-2555-2-21.
- Kim Y-G, Ihn J-C, Park S-K, Kyung HS. (2006) An arthroscopic analysis of lateral meniscal variants and a comparison with MRI findings. *Knee Surg Sports Traumatol Arthrosc.* 14(1): 20–26. Doi: 10.1007/s00167-005-0629-6.
- Kramer DE, Micheli LJ (2009) Meniscal Tears and Discoid Meniscus in Children: Diagnosis and Treatment. *J Am Acad Orthop Surg.* 17(11): 698–707. Doi:10.5435/00124635-200911000-0-0004.
- Lee YS, Teo SH, Ahn JH, Lee OS, Lee SH, Lee JH (2017). Systematic Review of the Long-term Surgical Outcomes of Discoid Lateral Meniscus. *J. Arthrosc. Relat. Surg.* 33(10): 1884–1895. Doi: 10.1016/j.arthro.2017.04.006.
- Perkins CA, Busch MT, Christino MA, Willimon SC (2021) Saucerization and

- Repair of Discoid Lateral Menisci with Peripheral Rim Instability: Intermediate-term Outcomes in Children and Adolescents. *J Pediatr Orthop* 41(1): 23–27. Doi: 10.1097/BPO.0000000000001695.
- Ryu K, Iriuchishima T, Oshida M, Saito A, Kato Y, Tokuhashi Y, Aizawa S (2015). Evaluation of the morphological variations of the meniscus: a cadaver study. *Knee Surg Sports Traumatol Arthrosc.* 23(1): 15–19. Doi: 10.1007/s00167-013-2612-y.
- Samoto N, Kozuma M, Tokuhisa T, Kobayashi K (2002). Diagnosis of discoid lateral meniscus of the knee on MR imaging. *Magnetic Resonance Imaging.* 20(1): 59–64. Doi: 10.1016/S073-0-725X(02)00473-3.
- Schonholtz GJ, Koenig TM and Prince A (1993). Bilateral discoid medial menisci: A case report and literature review. *J. Arthrosc. Relat. Surg.* 9(3): 315–319. Doi: 10.1016/S0749-8063(05)8042-7-X.
- Smillie IS (1948). The congenital discoid meniscus. *J Bone Joint Surg Br.* 30(4): 671–82.
- Taschdjian MO (1990). *Pediatric Orthopaedics* (ed. P Saunders). 2nd ed.
- Yamaguchi N, Chosa E, Tajima T, Morita Y, Yokoe T (2022). Symptomatic discoid lateral meniscus shows a relationship between types and tear patterns, and between causes of clinical symptom onset and the age distribution. *Knee Surg Sports Traumatol Arthrosc.* 30(4): 1436–1442. Doi: 10.1007/s00167-021-06635-3.